

**PATIENT PRESENTING CLINICAL SIGNS**

**PATIENT**  
 Bruno Ruddy  
 History: Vomiting. History of resolved dilated esophagus/esophagitis.

**SPECIES**  
 Canine  
 Physical Examination: N/A.

**BREED**  
 Mixed  
 Urinalysis: Normal.

**SEX**  
 MN  
 CBC: Normal.

**AGE**  
 6 years  
 Serum Biochemistry: Normal.

**WEIGHT**  
 53 #  
 Radiographic Findings: N/A.

**ULTRASONOGRAPHIC EXAMINATION OF THE ABDOMEN**

**Urinary System**

Full urinary bladder with a normal thickness and appearance of the wall. Normal anechoic urine with no sediment or uroliths evident.

Normal trigone area, proximal urethra, and iliac blood vessels.

Normal iliac lymph nodes. Ureters not visualized.

Normal renal size (left 6.3 cm, right 7.3 cm), echogenic appearance, cortico-medullary differentiation, blood flow, pelvis, and capsule.

**Reproductive System**

Small hypoechogenic prostate.

**Adrenal Glands**

Normal shape, echogenic appearance, position, and size.

**Spleen**

Normal size and echogenic appearance. Smooth homogenous parenchyma, regular capsule, and normal vasculature. No evidence of inflammatory, neoplastic, infarction, or infiltrative changes evident.

**Liver**

Normal size, echogenic appearance, portal markings, and regular curvilinear capsule. No nodules or masses evident.

**Gall bladder**

Full containing normal anechoic bile. Normal thickness and appearance of the wall. Normal bile duct.

**INTERPRETED BY**

Remo Lobetti, BVSc,  
 MMedVet (Med), PhD,  
 Dipl. ECVIM

**IMAGING PERFORMED BY**

Michelle Roche

**HOSPITAL NAME**

Fredon Animal Hospital

**REFERRING VET**

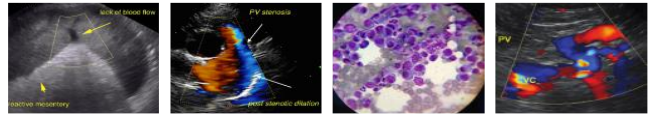
Michelle Roche

**INVOICE**

304077

**DATE**

4/4/23



**PATIENT**

Bruno Ruddy

**SPECIES**

Canine

**BREED**

Mixed

**SEX**

MN

**AGE**

6 years

**WEIGHT**

53 #

**INTERPRETED BY**

Remo Lobetti, BVSc,  
 MMedVet (Med), PhD,  
 Dipl. ECVIM

**IMAGING PERFORMED BY**

Michelle Roche

**HOSPITAL NAME**

Fredon Animal Hospital

**REFERRING VET**

Michelle Roche

**INVOICE**

304077

**DATE**

4/4/23

**Gastrointestinal**

Normal appearance of the stomach, duodenum, small intestine, ileo-cecal junction, and colon with no loss of layering, normal wall thickness and peristalsis, and no distension of the lumen. Small amount of fluid within the stomach.

**Pancreas**

Normal size and echogenic appearance. Regular capsule. Normal echogenic appearance of the mesentery and fat surrounding the pancreas.

**Free Abdomen**

No mesenteric lymphadenomegaly.  
 No ascites evident.

**ULTRASONOGRAPHIC FINDINGS**

Primary findings:

- Gastritis?

Secondary findings:

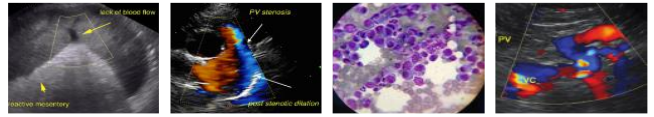
- None.

**INTERPRETATION OF THE FINDINGS & FURTHER RECOMMENDATIONS**

Although the fluid within the stomach may merely be an incidental finding, with the history, gastritis (dietary indiscretion, toxins, parasitic, *Helicobacter* gastritis, ulcerative gastritis, and inflammatory bowel disease) needs to be considered.

Further assessment would be fecal analysis and if there is not a satisfactory improvement with symptomatic therapy then endoscopy of the upper GI tract with biopsies.

Specific therapy would be dependent on an etiological diagnosis. Symptomatic management would be anti-emetics, gastric protectants (sucralfate, omeprazole), and an intestinal diet.



**PATIENT**

Bruno Ruddy

**SPECIES**

Canine

**BREED**

Mixed

**SEX**

MN

**AGE**

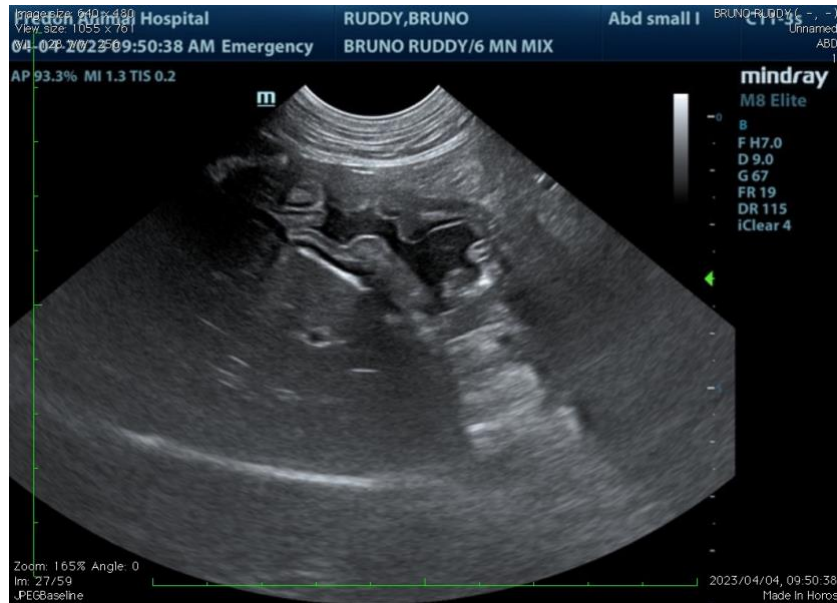6 years

**WEIGHT**

53 #

**IMAGES**

**Stomach**



**INTERPRETED BY**

Remo Lobetti, BVSc,  
 MMedVet (Med), PhD,  
 Dipl. ECVIM

**The information and recommendations provided are based on the images presented by the referring veterinarian. No evaluation can be communicated regarding pathology that was not visible in the image/video clips provided.**

Thank you for this referral. If the clinical or image interpretation does not parallel your findings or if I can be of any further assistance please contact me.

**Remo Lobetti, BVSc, MMedVet (Med), PhD, Dipl. ECVIM (Internal Medicine)**  
 rlobetti@mweb.co.za

**IMAGING PERFORMED BY**

Michelle Roche

**HOSPITAL NAME**

Fredon Animal Hospital

**REFERRING VET**

Michelle Roche

**INVOICE**

304077

**DATE**

4/4/23